



## Digital Breast Tomosynthesis for Intraoperative Margin Assessment during Breast-Conserving Surgery

Ko Un Park, MD<sup>1,6</sup>, Henry M. Kuerer, MD, PhD<sup>1</sup>, Gaiane M. Rauch, MD, PhD<sup>2</sup>, Jessica W. T. Leung, MD<sup>2</sup>, Aysegul A. Sahin, MD<sup>3</sup>, Wei Wei, MS<sup>4,5</sup>, Yisheng Li, PhD<sup>4</sup>, and Dallah M. Black, MD<sup>1</sup>

<sup>1</sup>Department of Breast Surgical Oncology, University of Texas MD Anderson Cancer Center, Houston, TX; <sup>2</sup>Department of Diagnostic Radiology, University of Texas MD Anderson Cancer Center, Houston, TX; <sup>3</sup>Department of Pathology, University of Texas MD Anderson Cancer Center, Houston, TX; <sup>4</sup>Department of Biostatistics, University of Texas MD Anderson Cancer Center, Houston, TX; <sup>5</sup>Taussig Cancer Institute, The Cleveland Clinic, Cleveland, OH; <sup>6</sup>*Present Address:* Department of Surgery, Division of Surgical Oncology, The Ohio State University, Columbus, OH

### ABSTRACT

**Background.** Intraoperative margin assessment for breast cancer patients undergoing segmental mastectomy (SM) enables identification of positive margins, with immediate excision of additional tissue to obtain negative margins.

**Objective.** The aim of this study was to determine the ability of digital breast tomosynthesis (DBT) to detect positive margins compared with an institution's standard extensive processing (SEP).

**Methods.** SM specimens underwent intraoperative SEP with two-dimensional (2D) imaging of the intact and sliced specimen, with review by a breast radiologist and gross assessment by a breast pathologist. Findings guided the surgeon to excise additional tissue. DBT images of intact specimens were prospectively obtained and retrospectively reviewed by a breast radiologist. A positive margin was defined as tumor at ink.

**Results.** Ninety-eight patients underwent 99 SMs. With SEP, 14 (14%) SM specimens had 19 positive margins. SEP did not detect 3 of the 19 positive margins, for a sensitivity of 84%, specificity of 78%, positive predictive value (PPV) of 11%, and negative predictive value (NPV) of 99%. Moreover, DBT did not detect 5 of the 19 positive

margins, for a sensitivity of 74% ( $p > 0.05$ ), specificity of 91% ( $p < 0.05$ ), PPV of 21.5%, and NPV of 99%. With SEP guidance to excise additional tissue, six cases had final positive margins, with SEP not identifying three of these cases and DBT not identifying two. Pathology from the second surgery of these patients showed either no additional malignancy or only focal ductal carcinoma in situ.

**Conclusions.** DBT is an accurate method for detecting positive margins in breast cancer patients undergoing SM, performing similar to institutional labor-intensive, intraoperative standard processing.

Advantages for breast cancer patients undergoing segmental mastectomy (SM) compared with mastectomy include similar local recurrence rates and survival with lower complications.<sup>1,2</sup> However, adequate local control with SM depends on obtaining negative margins and receipt of radiation.<sup>3,4</sup> Identifying positive margins intraoperatively using an efficient, accurate technique remains challenging, with re-excision rates up to 20–40%.<sup>5</sup> Additional surgery to obtain clear margins increases the risk of surgical complications, healthcare costs, and patient recovery time.<sup>6–8</sup>

SM margins are commonly assessed intraoperatively using gross evaluation and two-dimensional (2D) specimen imaging; however, this method is not accurate in identifying microscopic disease at the margins.<sup>6,9</sup> In a meta-analysis, the pooled sensitivity for margin assessment with 2D imaging was 53%, compared with a sensitivity of 86% for frozen section and 91% with touch preparation.<sup>10</sup>

Digital breast tomosynthesis (DBT) was approved by the Federal Drug Administration in 2011 for breast cancer screening. DBT creates a series of thin-sliced, 2D images

**Electronic supplementary material** The online version of this article (<https://doi.org/10.1245/s10434-019-07226-w>) contains supplementary material, which is available to authorized users.

© Society of Surgical Oncology 2019

First Received: 1 June 2018;  
Published Online: 14 March 2019

D. M. Black, MD  
e-mail: dmblack@mdanderson.org

with angular rotation to provide z-axis resolution, resulting in improved lesion conspicuity with increased cancer detection rates and fewer call backs.<sup>11-16</sup> It has been adapted into smaller portable units for obtaining intraoperative three-dimensional (3D) images of SM specimens.<sup>17</sup>

The aim of this study was to determine the ability of DBT to detect positive margins in breast cancer patients undergoing SM compared with an academic institution’s intraoperative standard extensive processing (SEP) that utilizes 2D specimen imaging.

**MATERIALS AND METHODS**

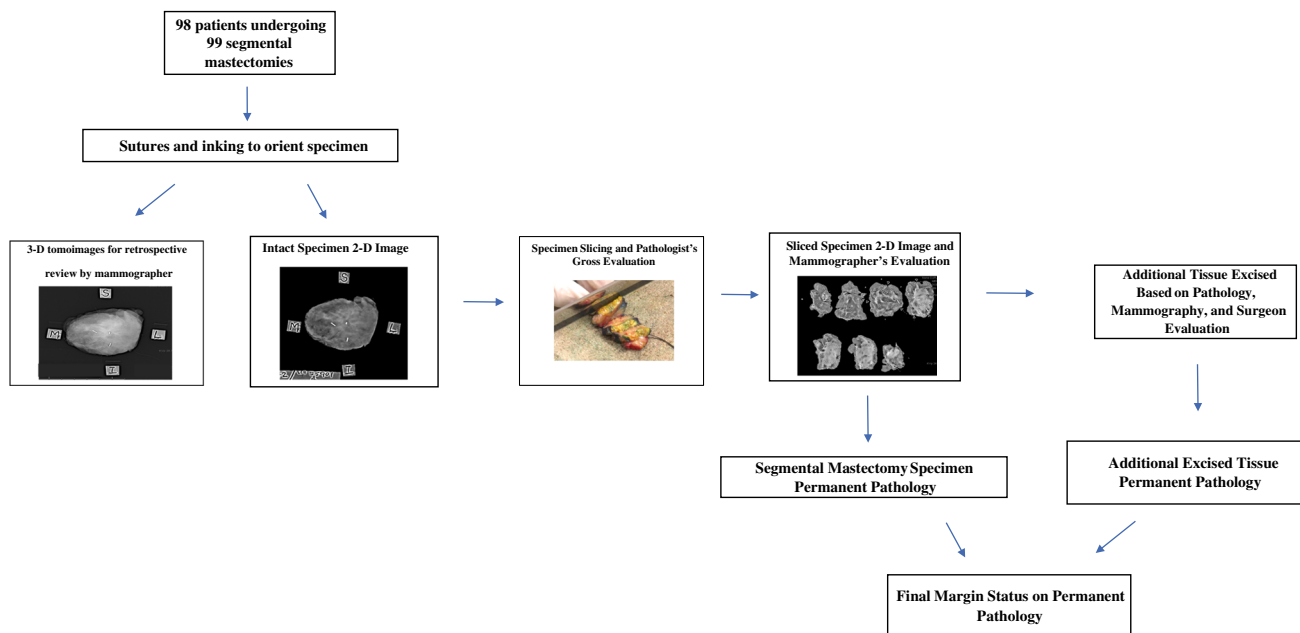
After approval from the University of Texas MD Anderson Cancer Center Institutional Review Board (IRB), we identified 98 patients who underwent 99 SMs between November 2016 and September 2017 with DBT specimen images. Patients were excluded if they had a complete response on final pathology after receiving preoperative systemic therapy as the images of these specimens had varying degrees of detectable residual abnormalities. Clinical, imaging, surgical, and pathology data were retrospectively analyzed.

Our institution’s SEP included four steps, as detailed in Fig. 1. Intact specimen films were acquired using 2D imaging (Faxitron MX20; Faxitron Bioptics, LLC, Tuscon, AZ, USA). The specimen was sectioned in 3–5 mm slices and the slices were also imaged. The pathologist’s and breast imager’s combined analysis of the specimen guided the surgeon’s excision of additional tissue targeted to the specific edge(s) interpreted by SEP as having tumor at

ink.<sup>18,19</sup> Excision of additional tissue was also at the discretion of the surgeon. If there was palpable nodularity in the lumpectomy bed of the remaining breast tissue, this tissue was also excised. Routine shave margins of the lumpectomy cavity were not performed.

Permanent margin status was determined by examining formalin-fixed, permanent paraffin-embedded sections, and margin width was reported in millimeters. A positive margin was defined as tumor at ink; a close margin was defined as malignancy 0.1 to ≤ 1.9 mm from the inked edge; and a negative margin was defined as malignancy ≥ 2.0 mm from the inked edge. Final margin status included permanent pathology of the primary specimen and permanent pathology of the additional excised tissue. For three cases where the primary specimen had tumor at the junction of multiple edges (i.e. anterior/lateral), these margins were considered as separate margins for statistical analysis.

DBT images of the intact SM specimen were acquired using the Mozart system (Kubtec Medical Imaging, Stratford, CT, USA) prior to serial sectioning of the specimen. Images were obtained using the standard tomosynthesis technique, which generated multiple low-dose projection images over a 30-degree arc and were reconstructed into a series of 1-mm sections to create a set of parallel slices. DBT images were stored and retrospectively reviewed by one of two breast radiologists. This retrospective review was not available for intraoperative specimen analysis and did not guide additional tissue excision. DBT images were not read by the breast surgeons.



**FIG. 1** Segmental mastectomy specimen processing for intra-operative and permanent pathology evaluation

To evaluate the accuracy of SEP and DBT for identifying SM primary specimens having tumor at ink, and correctly detecting the specific specimen edge having tumor at ink, sensitivity, specificity, false negative rate (FNR), positive predictive value (PPV), and negative predictive value (NPV) were calculated. The  $p$  values were calculated using McNemar's test, and a  $p$  value  $\leq 0.05$  was considered statistically significant.

## RESULTS

The median age of patients was 60.2 years (range 35–86), and the majority of patients had T1 invasive ductal cancer (IDC) (Table 1). Cancer mammogram presentation included architectural distortion ( $n = 18$ ), calcifications ( $n = 15$ ), asymmetry ( $n = 47$ ), or asymmetry with calcifications ( $n = 14$ ). Five cancers were occult on mammography and were detected on breast ultrasound or magnetic resonance imaging.

### *Institutional Standard Extensive Processing*

**Identifying Primary Specimens Having Tumor at Ink** On permanent pathology, 14 of the 99 SM primary specimens (14%) had tumor at ink at one or more of the specimen edges. All 14 of these primary specimens were identified by SEP for a sensitivity of 100%, specificity of 28%, FNR of 0%, PPV of 19%, and NPV of 100% (Table 2a).

**Determining the Primary Specimen Edge Having Tumor at Ink** On permanent pathology, 11 primary specimens had tumor at ink at one edge and three primary specimens had two or more edges with tumor at ink, for a total of 19 positive margins. SEP did not detect tumor at ink on the

edges of three primary specimens, resulting in an 84% sensitivity, specificity of 78%, FNR of 16%, PPV of 11%, and NPV of 99% (Table 2b). These three primary specimens (case numbers 78, 97, and 106) also had close margins, with SEP identifying only the close margins. SEP did not detect two primary specimens having an edge with ductal carcinoma in situ (DCIS) at ink and one primary specimen having an edge with IDC at ink. These three patients underwent a second surgery, with two having no malignancy and one having focal DCIS (Table 3). Of the 594 total margins on the 99 SM specimens in the cohort, 19 were positive and 575 were negative, resulting in 3.2% of the margins having tumor at ink.

**Interpreting the Edges of Primary Segmental Mastectomy (SM) Specimens as Having Tumor at Ink** Seventy-four of the 99 primary SM specimens were read by SEP as having tumor at ink. Additional tissue was excised at the specific edge of concern, with only 16 (21.6%) specimens having malignancy (7 with invasive cancer and 9 with DCIS), for a specificity of 28.2%.

Of the 85 primary specimens having no tumor at ink on permanent pathology, SEP interpreted seven (8%) specimens as having tumor at ink and that the additional excised tissue contained malignancy. Forty-one of these 85 primary specimens had malignancy 0.1 to  $\leq 1.9$  mm from ink. SEP interpreted eight (19.5%) of these primary specimens as having no tumor at the edge. For the remaining 33 primary specimens with a close edge, SEP interpreted them as having tumor at ink. In six of these primary specimens, SEP-directed excision of additional tissue contained malignancy (three cases with IDC and three with DCIS).

**Final Margin Status** Six of the 99 primary specimens had tumor at ink at a total of six final margins (includes the primary specimen and SEP-guided targeted excision of additional tissue), resulting in 6% of patients having a final positive margin. None of these six patients received preoperative chemotherapy or endocrine therapy. Four cases had IDC (two with T1 lesions and two with T2 lesions) and two cases had extensive DCIS.

Of the six cases with positive final margins, the additional excised tissue in three cases still had tumor at ink (cases numbers 2, 95, and 115), resulting in these patients returning to the operating room (OR). SEP did not identify three primary specimens having tumor at the inked edge, with two having DCIS at ink (case numbers 78 and 97) and one having IDC at ink (case number 106). These three patients underwent a second surgery and only one (case number 106) had focal DCIS (Table 3). In total, 10 patients underwent a second surgery for tumor at ink or close margins, with eight having a re-excision SM and two having mastectomy.

**TABLE 1** Tumor histology and size on segmental mastectomy permanent pathology

Histology	No. of cases
Invasive ductal	74
Invasive lobular	5
Mixed invasive ductal/lobular	5
Phyllodes	2
Ductal carcinoma in situ	12
Pleomorphic lobular carcinoma in situ	1
T stage	
Tis	13
T1	68
T2	17
T3	1

Tis in situ disease, T tumor

**TABLE 2** Comparison of SEP and DBT for identifying positive margins

<i>(a) Identifying SM specimens having tumor at an inked edge using SEP or DBT</i>						
SM permanent pathology ( <i>n</i> = 99)	SEP interpreted as no tumor at ink ( <i>N</i> = number of SM specimens)	SEP interpreted as having tumor at ink ( <i>N</i> = number of SM specimens)	DBT interpreted as no tumor at ink ( <i>N</i> = number of SM specimens)	DBT interpreted as having tumor at ink ( <i>N</i> = number of SM specimens)	DBT interpreted edge(s) as having tumor at ink ( <i>N</i> = number of SM specimens)	<i>p</i> value
SM with no tumor at ink ( <i>n</i> = 85)	24	61	66	19		> 0.05
SM with one or more edges having tumor at ink ( <i>n</i> = 14)	0	14	1	13		< 0.0001
	SEP (%)	SEP (%)	DBT (%)	DBT (%)		> 0.05
Sensitivity	100		92.9			< 0.0001
Specificity	28.2		77.6			> 0.05
False negative rate	0		7.1			
Positive predictive value	18.7		40.6			
Negative predictive value	100		98.5			
<i>(b) Determining the location of the SM edge having tumor at ink using SEP or DBT</i>						
Permanent pathology of individual SM edges ( <i>n</i> = 594)	SEP interpreted as no tumor at ink ( <i>N</i> = number of SM specimens)	SEP interpreted edge(s) as having tumor at ink ( <i>N</i> = number of SM specimens)	DBT interpreted as no tumor at ink ( <i>N</i> = number of SM specimens)	DBT interpreted edge(s) as having tumor at ink ( <i>N</i> = number of SM specimens)	DBT interpreted edge(s) as having tumor at ink ( <i>N</i> = number of SM specimens)	<i>p</i> value
Edges with no tumor at ink ( <i>n</i> = 575)	448	127	524	51		0.32
Edges having tumor at ink ( <i>n</i> = 19)	3	16	5	14		< 0.0001
	SEP (%)	SEP (%)	DBT (%)	DBT (%)		0.32
Sensitivity	84.2		73.7			< 0.0001
Specificity	77.9		91.1			0.32
FNR	15.8		26.3			
Positive predictive value	11.2		21.5			
Negative predictive value	99.3		99.1			

TABLE 2 continued

<i>(c) Comparison of SEP and DBT for accurately assessing SM edges having tumor at ink or no tumor at ink</i>					
	DBT interpreting a pathologic edge as having no tumor at ink ( <i>n</i> = number of SM edges)	DBT interpreting a pathologic negative edge as having tumor at ink ( <i>n</i> = number of SM edges)	DBT interpreting a pathologic negative edge as having no tumor at ink ( <i>n</i> = number of SM edges)	DBT interpreting a pathologic positive edge as having tumor at ink ( <i>n</i> = number of SM edges)	DBT interpreting a pathologic positive edge as having no tumor at ink ( <i>n</i> = number of SM edges)
SEP interpreting a pathologic negative edge as having no tumor at ink	433	15	—	—	—
SEP interpreting a pathologic negative edge as having tumor at ink	91	36	—	—	—
SEP interpreting a pathologic positive edge as having no tumor at ink	—	—	2	1	1
SEP interpreting a pathologic positive edge as having tumor at ink	—	—	3	13	13

*SEP* standard extensive processing, *DBT* digital breast tomosynthesis, *SM* segmental mastectomy, *n* number

### Digital Breast Tomosynthesis

*Identifying Primary Specimens Having Tumor at Ink* Of the 14 primary SM specimens having tumor at ink, 13 were identified by DBT. The one case not identified by DBT (case number 97) had IDC and extensive DCIS, with the medial specimen edge having DCIS at ink. SEP identified this specimen as having tumor at ink but interpreted the lateral edge as being close for malignancy and did not identify the specimen's medial edge as having DCIS at ink. The additional excised lateral tissue contained only focal DCIS. The patient returned to the OR for excision of medial tissue which only contained focal atypical ductal hyperplasia (ADH) (electronic supplementary Fig. 1).

*Determining the Edge on the Primary Specimen Having Tumor at Ink* Of the 14 primary SM specimens having tumor at ink at 19 edges, DBT detected 14 of these edges, for a sensitivity of 74%, specificity of 91%, FNR of 26%, PPV of 21.5%, and NPV of 99% (Table 2b). Both SEP and DBT interpretations would have resulted in three patients having tumor at ink, necessitating a second surgery. Of these, two primary specimens (case numbers 78 and 97) had extensive DCIS that neither SEP nor DBT detected. In case number 78, the patient underwent a second surgery, with no malignancy identified. For the positive DCIS edge of primary specimen number 97, the patient's second surgery only showed focal ADH (Table 3). For the third primary specimen (case number 82), DBT did not detect its medial edge that had invasive disease at ink, but SEP did. SEP-guided excision of additional medial tissue had a 3.5 mm IDC foci (electronic supplementary Fig. 2).

DBT detected one of the three primary specimens having tumor at ink (case number 106, with IDC) that was not detected by SEP (Fig. 2). The patient underwent a second surgery, and excision of tissue at the area of concern contained only focal DCIS.

*Interpreting the Edges of Primary SM Specimens as Having Tumor at Ink* DBT interpreted 32 of the 99 primary specimens as having tumor at ink, while SEP interpreted 74 specimens as having tumor at ink. Only 16 primary specimens had malignancy in SEP-directed additional excised tissue, of which 11 were also identified by DBT. For the five primary specimens that DBT did not identify as having tumor at ink, SEP-directed excision of additional tissue contained only focal DCIS in four cases. The fifth primary specimen had a 5.5 cm invasive lobular cancer (ILC), with SEP-directed excision of additional tissue containing a 3 mm and 1 mm ILC foci. For identifying primary specimens having tumor at ink, DBT had a sensitivity of 92.9%, specificity of 77.6%, FNR of 7.1%, PPV of 40.6%, and NPV of 98.5% (Table 2a).

**TABLE 3** Comparison of permanent pathology, SEP, and DBT for the six segmental mastectomy patients with final positive margins undergoing a second surgery

Case ID number	Mammogram finding	Localization method	SM pathology and margin status	Additional excised tissue pathology and margin status	SEP-interpreted (+) margins for SM	DBT-interpreted (+) margins for SM	Second surgery performed
2	Architectural distortion	Mammogram-guided radioactive seed	Clip and seed (no malignancy)	Inferior: 4 mm IDC at margin Lateral (-) Superior (-) Anterior (-) Posterior (-)	Inferior Lateral Superior Anterior-Posterior	Inferior Lateral Superior Anterior	Re-excision SM: inferior (-)
78	Density	Palpation	Extensive DCIS: (+) margin: lateral/anterior <sup>a</sup> < 1 mm margins: posterior, inferior, medial <sup>a</sup>	Inferior/posterior: extensive DCIS < 2 mm from margin	Inferior Posterior	Posterior	Re-excision SM: Medial: focal DCIS Posterior (-) Inferior (-) Lateral/anterior (-)
95	Density	ULS-guided radioactive seed	Extensive DCIS: (+) margin: posterior	Posterior: extensive DCIS at margin	Posterior	Posterior	Total mastectomy: extensive DCIS
97	Density and calcifications	Mammogram-guided wire	IDC with extensive DCIS: (+) margin: medial DCIS <sup>a</sup> < 1 mm margins: anterior: IDC; posterior, lateral: DCIS <sup>b</sup>	Lateral: focal DCIS	Lateral	None	Re-excision SM: medial: focal ADH posterior (-)
106	None (MRI detected)	ULS-guided radioactive seed	IDC: (+) margin: medial <sup>c</sup> < 1 mm margin: superior	Superior (-) Inferior (-) Posterior (-)	Superior Posterior	Superior Medial Inferior	Re-excision SM: medial: focal DCIS
115	Density	Palpation	Mixed IDC/ILC: (+) margin: lateral, inferior	Lateral: 5 mm mixed IDC/ILC Inferior: 5 mm mixed IDC/ILC at margin posterior (-)	Lateral Inferior Posterior	Lateral Inferior	Re-excision SM: inferior (-)

SEP standard extensive processing, DBT digital breast tomosynthesis, MRI magnetic resonance imaging, ULS ultrasound, SM segmental mastectomy, DCIS ductal carcinoma in situ, IDC invasive ductal cancer, ILC invasive lobular cancer, ADH atypical ductal hyperplasia, + indicates positive, - indicates negative

<sup>a</sup>(+) or close margin missed by SEP and DBT

<sup>b</sup>Close margin missed by DBT

<sup>c</sup>(+) margin missed by SEP

Of the 85 primary specimens having no tumor at ink on permanent pathology, seven had malignancy in SEP-directed additional excised tissue (three invasive and four DCIS), which is consistent with some cancers being multifocal. DBT identified four of these seven primary specimens.

## DISCUSSION

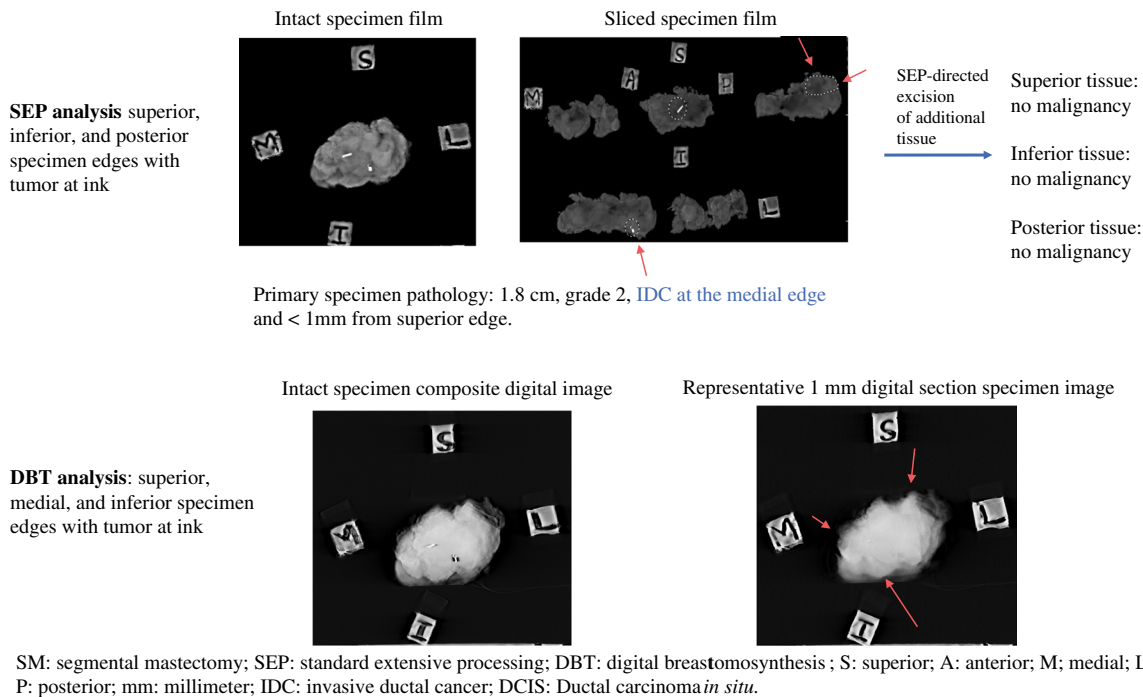
This study demonstrates the ability of DBT to accurately identify SM specimens having tumor at ink, with a similar sensitivity and higher specificity compared with our institutional SEP. Both methods detected the majority of SMs having tumor at ink, and, similarly, did not detect edges having minimal focal disease. The disadvantages of SEP include lower specificity, as it often recommended excision of additional tissue unnecessarily, it is labor intensive, and has a longer OR time; however, SEP resulted in a small number of second surgeries. DBT is not resource-intensive, although it identified positive margins similar to SEP but with statistically higher specificity, which decreases the amount of additional tissue excised unnecessarily. DBT can replace labor-intensive processing methods given that its rapid acquisition of high resolution, cross-sectioned images of the intact specimen takes approximately 1 min, and can be read by the surgeon.

In an international, prospective study of 102 cases by Amer et al., including SM specimen images reviewed by a radiologist, DBT performance was similar to our study's

findings for identifying positive margins, with a 77% sensitivity and 98% specificity, compared with 2D specimen imaging sensitivity of 62% and specificity of 77% ( $p = 0.03$ ).<sup>23</sup> Schulz-Wendtland et al. retrospectively compared 2D specimen imaging with DBT, which had a higher sensitivity and lower rate of re-excisions compared with 2D specimen imaging.<sup>24</sup>

To achieve negative margins, other institutions perform routine cavity shave margins by excising additional tissue at all of the lumpectomy edges.<sup>20,21</sup> This procedure does not require a pathologist or radiologist intraoperatively. Its longer OR time and higher pathology costs have been reported as being similar to SM without shave margins, given the latter's higher number of second surgeries to obtain negative margins.<sup>22</sup>

To compare SEP, DBT, and cavity shave margins, SEP identified all 14 SMs having tumor at ink, while DBT identified 13; theoretically, the shave margin approach would have identified all 14 specimens. Of the 19 positive SM edges, SEP identified 16 and DBT identified 14; theoretically, routine shave margins would have identified all 19 edges. Of the 85 specimens with negative edges, SEP interpreted 61 as having tumor at ink and DBT interpreted 19; theoretically, the routine shave margin approach would have interpreted all 85 negative specimens as having tumor at ink. Of the 594 total edges in the 99 SM specimens, 575 edges had no tumor at ink. SEP interpreted 127 of these negative edges as positive and DBT interpreted 51 negative edges as positive; theoretically, the shave margin approach



**FIG. 2** Primary SM specimen with tumor at ink medially not detected by SEP but detected by DBT

would have considered all 575 negative edges as positive. Routine shave margins would have theoretically required excising 575 negative margins in order to include the 19 positive margins. In a randomized study comparing routine cavity shave margins or no routine shave margins, Chagpar et al. found that 10% of patients having routine shave margins returned for a second surgery, compared with 21% of those not having routine shave margins.<sup>21</sup> In our study, only 14% of the initial SM specimens had a positive margin, which is lower than both of the two groups in the randomized shave margin study. SEP had 127 negative margin excisions, with 16 of the 19 positive margins excised; three patients (3%) would have needed a second surgery for the positive margin not detected by SEP. DBT had 51 negative margins excised, with 14 of the 19 positive margins excised; five patients would have needed a second surgery for the positive margin not detected by DBT.

Our study has several limitations. It included 99 cases, which reflects approximately 6% of the SMs performed at our institution during this study period. In three studies of SM patients treated at our institution, close or positive margins ranged from 5.8 to 20%, with 9% of patients undergoing re-excision.<sup>25–27</sup> The 6% of SM-positive margins in the current study, with 10% of patients undergoing a second surgery for a close or positive margin, is comparable to our institution's prior publications in larger cohorts. In addition, DBT specimen images were retrospectively read by the breast radiologist and did not guide intraoperative analysis.

## CONCLUSIONS

DBT is an accurate technology for detecting the location of SM-positive margins, performing similar to institutional labor-intensive processing. It provides targeted excision of additional tissue in contrast to performing routine shave margins. A prospective study in a larger cohort is needed to evaluate the ability of surgeons to intraoperatively identify SM specimen positive margins utilizing DBT compared with SEP.

**ACKNOWLEDGMENT** The authors would like to thank Arnold Dahay, Davis Parambil, and Koreene Rockwood, histopathology technicians, for their contribution in processing the specimens for this study.

**DISCLOSURE** Wei Wei's work was generously supported by The Cancer Centre Support Grant from National Institute for Health/National Cancer Institute grant P30CA016672. Ko Un Park, Henry M. Kuerer, Gaiane M. Rauch, Jessica W. T. Leung, Aysegul A. Sahin, Yisheng Li, and Dalliah M. Black have no relevant financial disclosures to declare.

## REFERENCES

1. Fisher B, Anderson S, Bryant J, et al. Twenty-year follow-up of a randomized trial comparing total mastectomy, lumpectomy, and lumpectomy plus irradiation for the treatment of invasive breast cancer. *N Engl J Med*. 2002;347(16):1233–1241.
2. Veronesi U, Cascinelli N, Mariani L, et al. Twenty-year follow-up of a randomized study comparing breast-conserving surgery with radical mastectomy for early breast cancer. *N Engl J Med* 2002;347(16):1227–1232.
3. Houssami N, Macaskill P, Marinovich ML, et al. Meta-analysis of the impact of surgical margins on local recurrence in women with early-stage invasive breast cancer treated with breast-conserving therapy. *Eur J Cancer* 2010;46(18):3219–3232.
4. Early Breast Cancer Trialists' Collaborative Group (EBCTCG), Darby S, McGale P, Correa C, et al. Effect of radiotherapy after breast-conserving surgery on 10-year recurrence and 15-year breast cancer death: meta-analysis of individual patient data for 10,801 women in 17 randomised trials. *Lancet*. 2011;378(9804):1707–16.
5. Morrow M, Abrahamse P, Hofer TP, et al. Trends in reoperation after initial lumpectomy for breast cancer: addressing overtreatment in surgical management. *JAMA Oncol*. 2017;3:1352–1357.
6. Reyna C, DeSnyder SM. Intraoperative margin assessment in breast cancer management. *Surg Oncol Clin N Am*. 2018;27:155–165.
7. Yu J, Elmore LC, Cyr AE, Aft RL, Gillanders WE, Margenthaler JA. Cost analysis of a surgical consensus guideline in breast-conserving surgery. *J Am Coll Surg*. 2017;225(2):294–301.
8. Singer L, Brown E, Lanni T Jr. Margins in breast conserving surgery: The financial cost & potential savings associated with the new margin guidelines. *Breast*. 2016;28:1–4.
9. Jung W, Kang E, Kim SM et al. Factors associated with re-excision after breast-conserving surgery for early-stage breast cancer. *J Breast Cancer* 2012;15:412–419.
10. St John ER, Al-Khudairi R, Ashrafian H et al. Diagnostic accuracy of intraoperative techniques for margin assessment in breast cancer surgery: a meta-analysis. *Ann Surg*. 2017;265:300–310.
11. Lei J, Yang P, Zhang L et al. Diagnostic accuracy of digital breast tomosynthesis versus digital mammography for benign and malignant lesions in breasts: a meta-analysis. *Eur Radiol*. 2014;24:595–602.
12. Eghtedari M, Tsai C, Robles J et al. Tomosynthesis in breast cancer imaging: how does it fit into preoperative evaluation and surveillance? *Surg Oncol Clin N Am*. 2018;27:33–49.
13. Bernardi D, Macaskill P, Pellegrini M et al. Breast cancer screening with tomosynthesis (3D mammography) with acquired or synthetic 2D mammography compared with 2D mammography alone (STORM-2): a population-based prospective study. *Lancet Oncol*. 2016;17:1105–1113.
14. McDonald ES, Oustimov A, Weinstein SP et al. Effectiveness of digital breast tomosynthesis compared with digital mammography: outcomes analysis from 3 years of breast cancer screening. *JAMA Oncol* 2016;2:737–743.
15. Hodgson R, Heywang-Köbrunner SH, Harvey SC et al. Systematic review of 3D mammography for breast cancer screening. *Breast* 2016;27:52–61.
16. Seo N, Kim HH, Shin HJ et al. Digital breast tomosynthesis versus full-field digital mammography: comparison of the accuracy of lesion measurement and characterization using specimens. *Acta Radiologica* 2014;55:661–667.
17. Urano M, Shiraki N, Kawai T et al. Digital mammography versus digital breast tomosynthesis for detection of breast cancer in the intraoperative specimen during breast-conserving surgery. *Breast Cancer* 2016;23:706–711.



18. Schnitt SJ, Connolly JL. Processing and evaluation of breast excision specimens. A clinically oriented approach. *Am. J. Clin. Pathol.* 1992;98:125–137.
  19. Chagpar A, Yen T, Sahin A et al. Intraoperative margin assessment reduces reexcision rates in patients with ductal carcinoma in situ treated with breast-conserving surgery. *Am. J. Surg.* 2003;186:371–377.
  20. Mukhtar RA, Wong J, Piper M, Zhu Z, Fahrner-Scott K, Mamounas M, et al. Breast conservation and negative margins in invasive Lobular Carcinoma: the impact of oncoplastic surgery and shave margins in 358 patients. *Ann Surg Oncol.* 2018;25(11):3165–3170.
  21. Chagpar AB, Killelea BK, Tsangaris TN, Butler M, Stavris K, Li F, et al. A randomized, controlled trial of cavity shave margins in breast cancer. *N Engl J Med.* 2015;373(6):503–10.
  22. Chagpar AB, Horowitz NR, Killelea BK, Tsangaris T, Longley P, Grizzle S, et al. Economic impact of routine cavity margins versus standard partial mastectomy in breast cancer patients: results of a randomized controlled trial. *Ann Surg.* 2017;265(1):39–44.
  23. Amer HA, Schmitzberger F, Ingold-Heppner B et al. Digital breast tomosynthesis versus full-field digital mammography— which modality provides more accurate prediction of margin status in specimen radiography? *Eur. J. Radiol.* 2017;93:258–264.
  24. Schulz-Wendtland R, Dilbat G, Bani M et al. Full Field Digital Mammography (FFDM) versus CMOS technology versus tomosynthesis (DBT)—which system increases the quality of intraoperative imaging? *Geburtshilfe Frauenheilkd.* 2012;72(6):532–538.
  25. Cabioglu N, Hunt KK, Sahin AA et al. Role for intraoperative margin assessment in patients undergoing breast-conserving surgery. *Ann. Surg. Oncol.* 2007;14:1458–1471.
  26. Carter SA, Lyons GR, Kuerer HM, Bassett RL Jr, Oates S, Thompson A, et al. Operative and oncologic outcomes in 9861 patients with operable breast cancer: single-institution analysis of breast conservation with oncoplastic reconstruction. *Ann. Surg. Oncol.* 2016;23(10):3190–8.
  27. Tevis SE, Neuman HB, Mittendorf EA, Kuerer HM, Bedrosian I, DeSnyder SM, et al. Multidisciplinary intraoperative assessment of breast specimens reduces number of positive margins. *Ann. Surg. Oncol.* 2018;25(10):2932–2938.
- Publisher's Note** Springer Nature remains neutral with regard to jurisdictional claims in published maps and institutional affiliations.